Digestive system
(GIT-207)
Histology
Oral cavity and Salivary glands

Ass.Prof. Dr. Safaa Said

Department of Histology &Cell Biology

Assuit University

Learning objectives

Recognize	**Recognize and identify the parts of the digestive system**
Discuss	**Discuss the normal structure of oral mucosa.**
List	**List the names of salivary glands.**
Differentiate	Differentiate between the structure of the major salivary gland

• **The digestive tract** is a tubular passageway that extends from mouth opening to anus and is divisible into the following regions:

- **Oral cavity**
- **Pharynx**
- **Esophagus**

• **Gastrointestinal tract;** divided into 3 regions

- Gastric gland (stomach)
- Small intestine
- Large intestine, anal canal, anus

• **The accessory digestive glands** The three principle sets of glands ;

- Extrinsic salivary glands
- Liver and gall bladder
- Pancreas

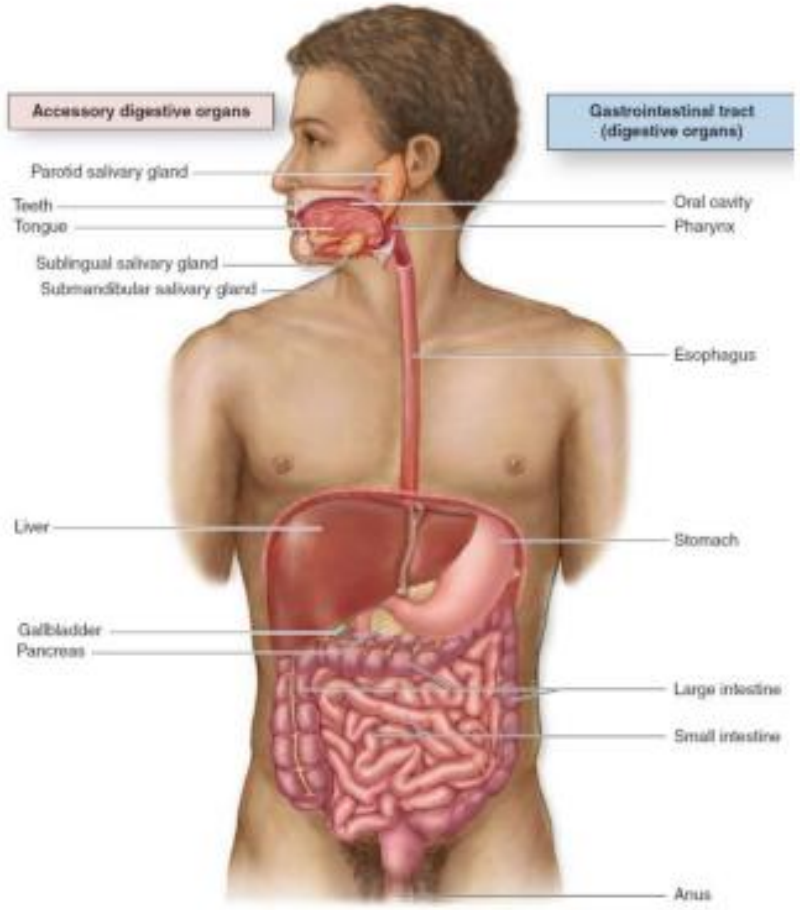

Oral cavity and associated structures

- **The oral cavity includes :**
- **the lips; palate; teeth and associated structures; tongue; major salivary glands; and tonsils.**

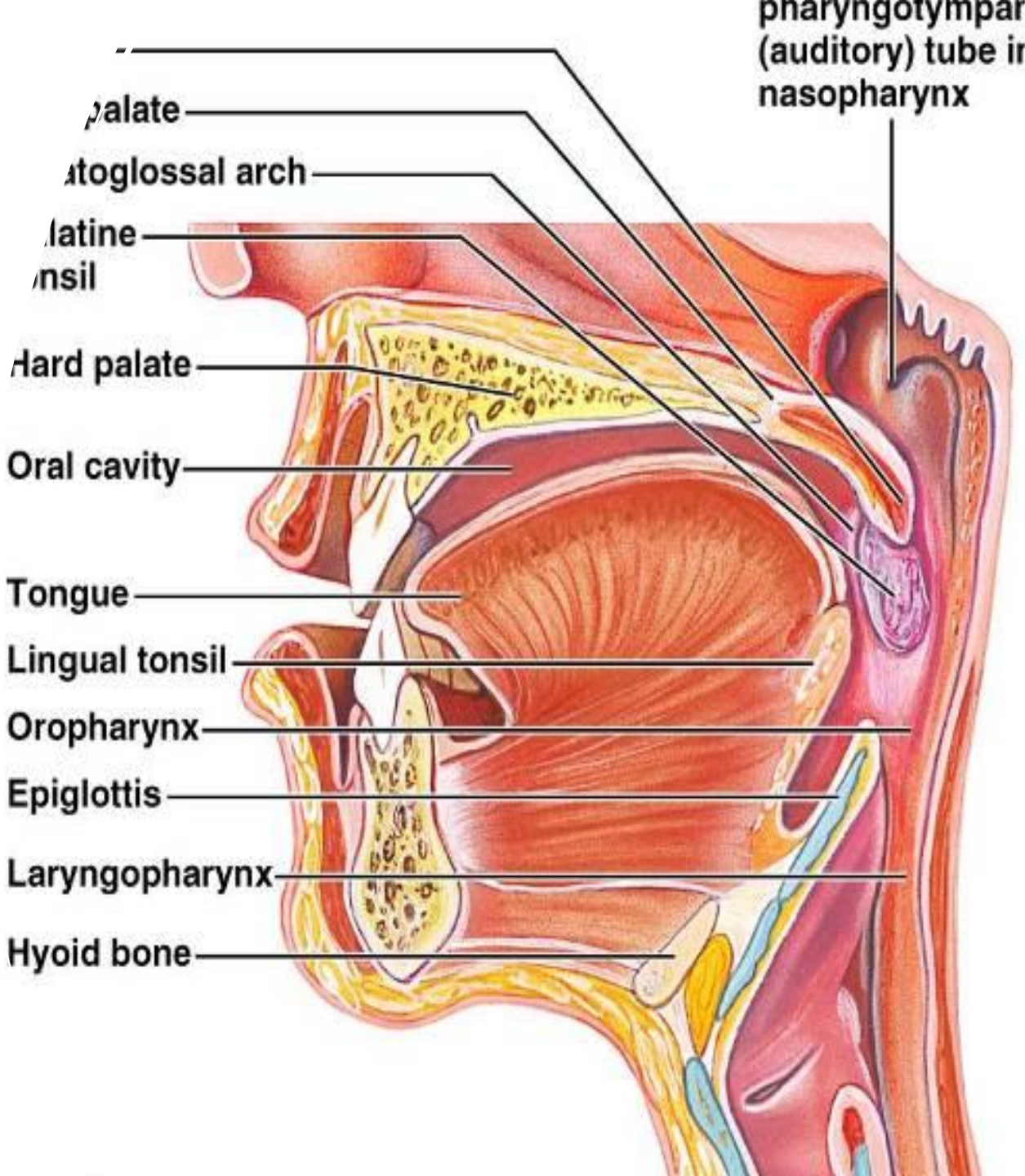

Oral cavity

- **The oral cavity is lined in most places by a stratified squamous epithelium and an underlying connective tissue ,lamina propria. The epithelium and the underlying connective tissue together form the oral mucosa.**
- **The oral cavity has three types of mucosae:**

- Lining mucosa: epithelium is non-keratinized; soft palate, lips, cheeks, and the floor of the mouth

- Masticatory mucosa: epithelium is keratinized as in gingiva (gum) and hard palate.

- Specialized mucosa, restricted to the dorsum of the tongue and possesses papillae and taste buds.

Lips

- Extend from inferior margin of the nose to the superior margin of the chin.
- Red area = red margin, is poorly keratinized & lacks sweat or sebaceous glands.
- The core of the lip is composed of skeletal muscle fibers (orbicularis oris).
- In sagittal section, the lip appears to be formed of 3 regions.
  - The external aspect (skin surface): covered with thin skin.
  - The virmilion border or the red margin: covered with modified thin skin which is devoid of hair follicles and sweat glands.
  - The mucous surface: It is lined by stratified squamous non keratinized epithelium.

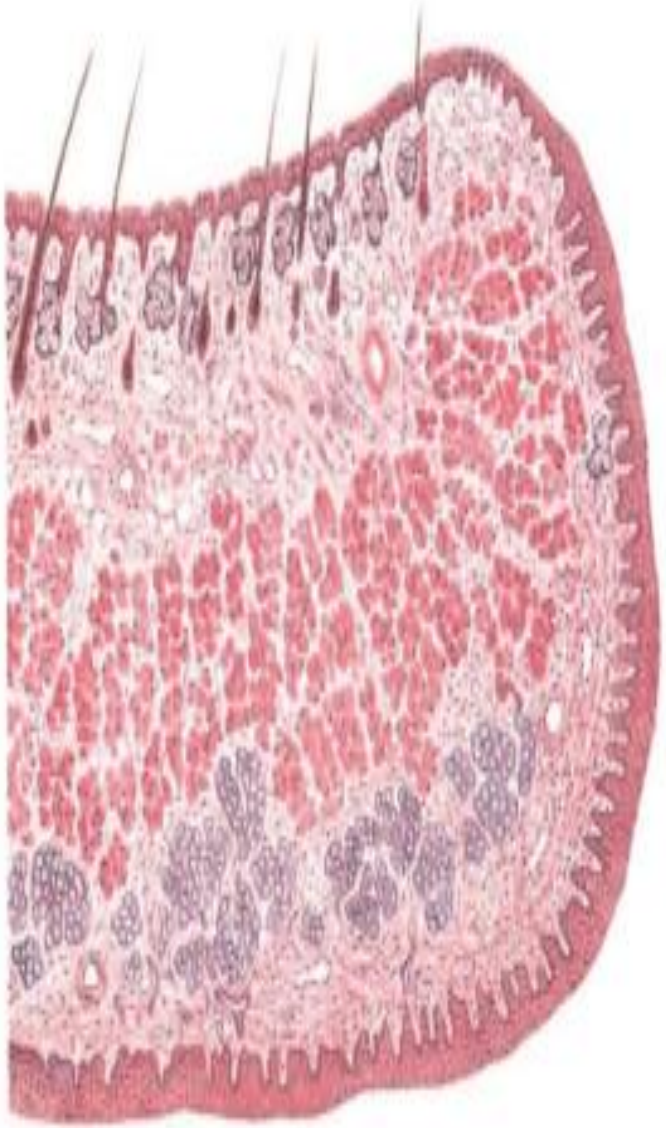

Palate

Palate:

- **Hard palate:** rigid surface against which food is forced in chewing
- **Soft palate**: muscular structure that rises & blocks off the nasopharynx during swallowing

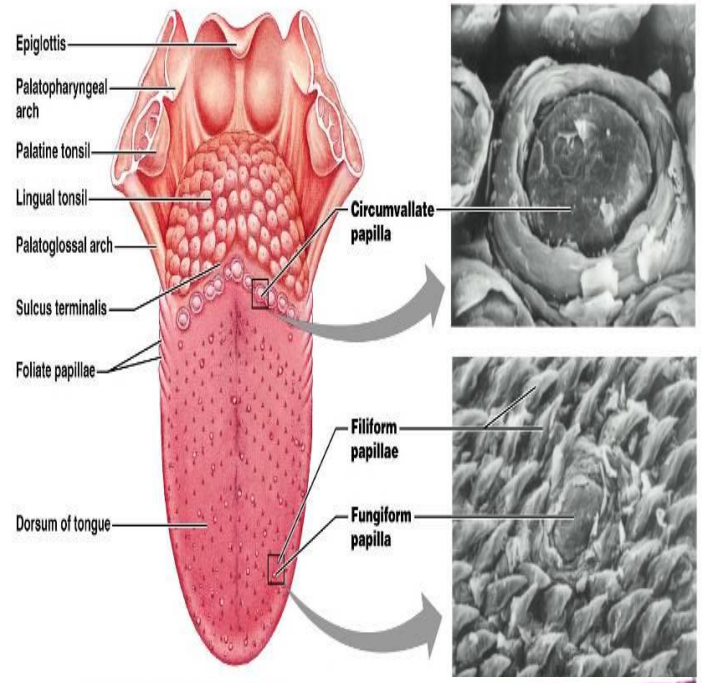

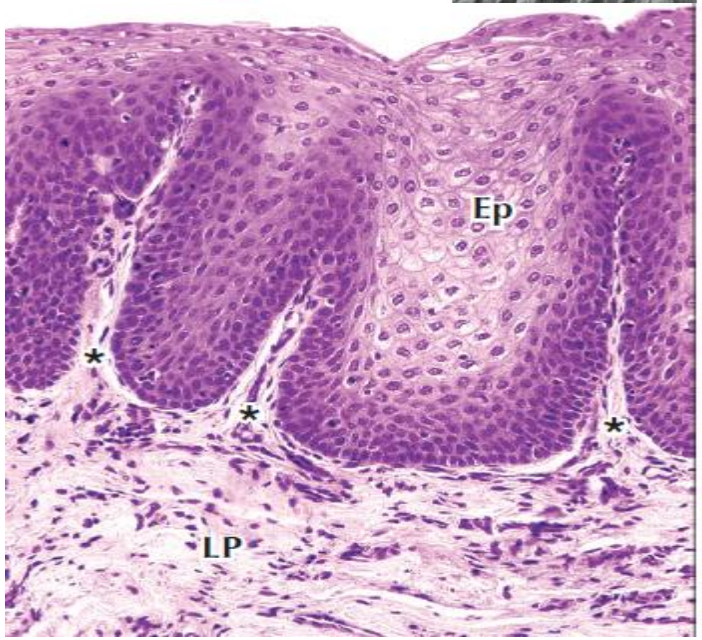

The tongue

- **The tongue is a mass of striated muscle covered by a mucous membrane.**
- **The ventral surface is covered by non-keratinized stratified squamous epithelium, while Its dorsal surface is covered by stratified squamous keratinized epithelium.**
- **The dorsal surface has v-shaped groove (sulcus terminalis)**
- **The sulcus divides the dorsal surface into an anterior 2/3 and a posterior 1/3**
- **The anterior 2/3 is irregular, covered anteriorly by a great number of small eminences called papillae**
- **The posterior 1/3 surface shows the many bulges of the lingual tonsils.**

Lingual papillae:

They are formed of a central core of C.T. and a covering layer of stra squamous epithelium.

Types: according to their shape, there are 4 types of papillae:

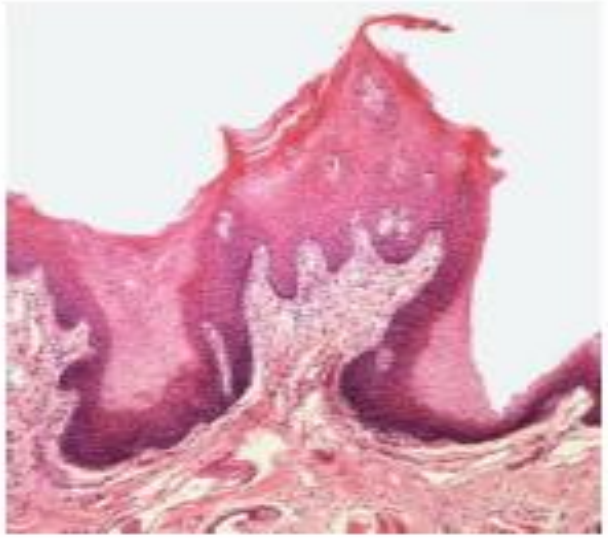

- **Filiform papillae:**

Most numerous and found all over the dorsal surface of the tongue.

They are tall, narrow, pointed and highly keratinized structures.

These papillae are lacking taste buds.

They provide rough surface that facilitates movement of food during chewing

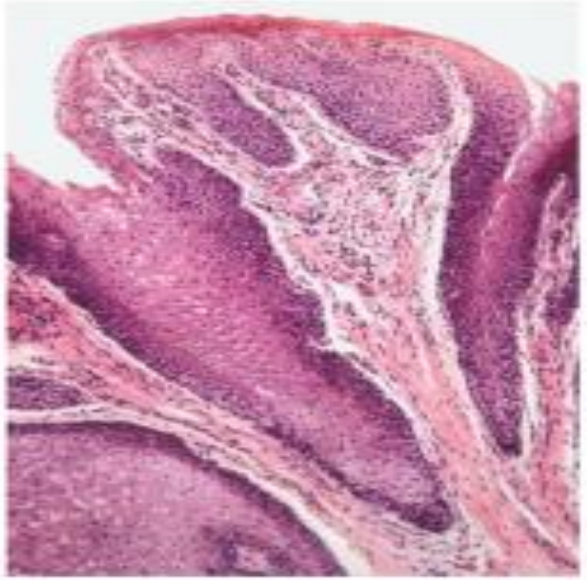

Lingual papillae:

.Fungiform papillae:

- **Fungiform papillae are mushroom-shaped structures.**
- **Covered by non-keratinized squamous epithelium.**
- **They are interspersed in the tip and sides. This type of papillae contains taste buds.**

- **Circumvallate papillae (Vallate papillae)**
- Arranged in a single row, which contains about 10 to 14 papillae that are located immediately anterior to the sulcus terminalis.
- Cylindrical in shape and is surrounded by a groove called a moat.
- Ducts of the glands of von Ebner (serous glands); this he to clear the food debris in the groove and helps in detection of taste.

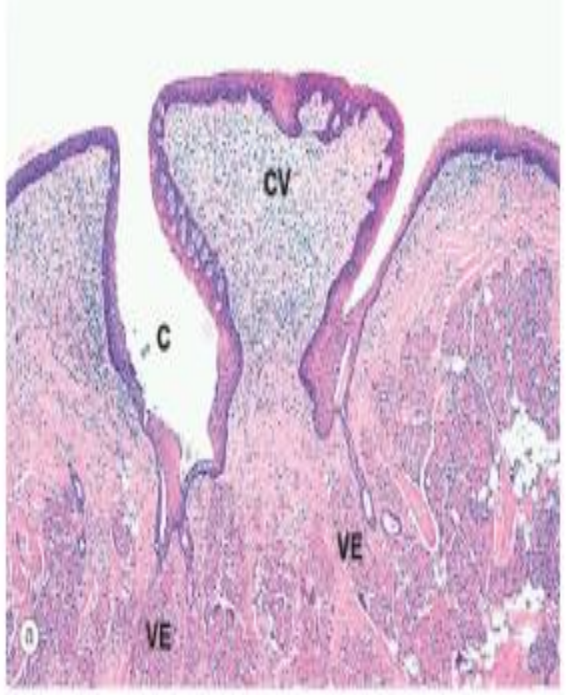

- **Foliate papillae:**
- These papillae are poorly developed in adults.
- They consist of parallel ridges and furrows located on the posterior lateral surface of the tongue and they contain taste buds.

Taste buds:

- They are specialized sensory receptors (chemoreceptors);
- they are located in the epithelium of the tongue (in all mentioned papillae except keratinized filiform), they are also present in soft palate, pharynx & epiglottis.
- The taste buds are oval in shape, pale in staining. At the apical part, it opens in a very small/minute opening called "Taste pore" or"Gustatory pore".

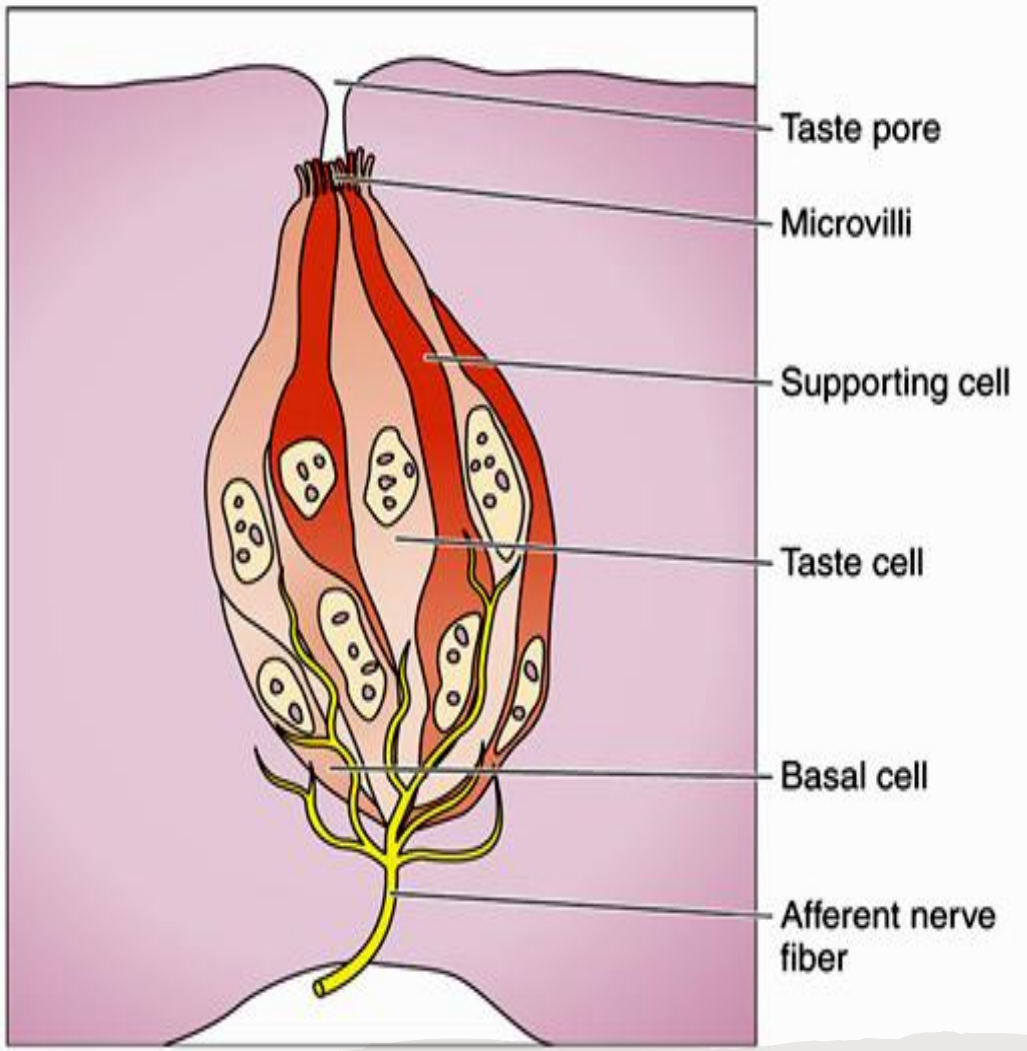

Taste buds:

- By light microscope; Taste buds are oval, pale-staining structures that extend through much of the thickness of the epithelium.
- Beneath the taste bud are nerve fibers.

At the apex of the taste bud, there is a small opening in the epithelium which is the taste pore.

Taste buds have 3 types of cells;

- The gustatory (neuroepithelial sensory) cells,
- The supporting cells and
- The basal stem cells .

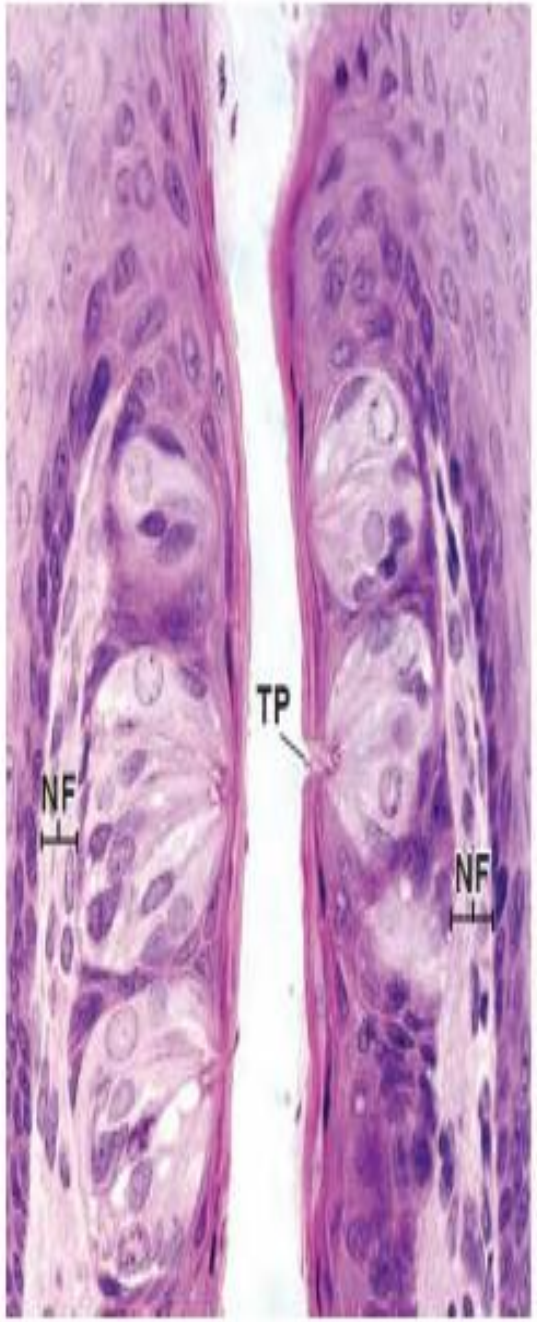

1-Supporting cells: Their function is supporting for taste buds. They are slender cells extending from the basal lamina to the taste pore where they have numerous microvilli.

2-Taste cells (gustatory cells) They are light because their cytoplasm contains few filaments, and apical microvilli.

They are characterized by the presence of numerous synaptic vesicles in their basal cytoplasm. Dendritic processes of sensory nerves are found in close proximity to these vesicles.

3-Undifferentiated basal cells They are found in the base of the taste buds. They are the precursor of the other cells.

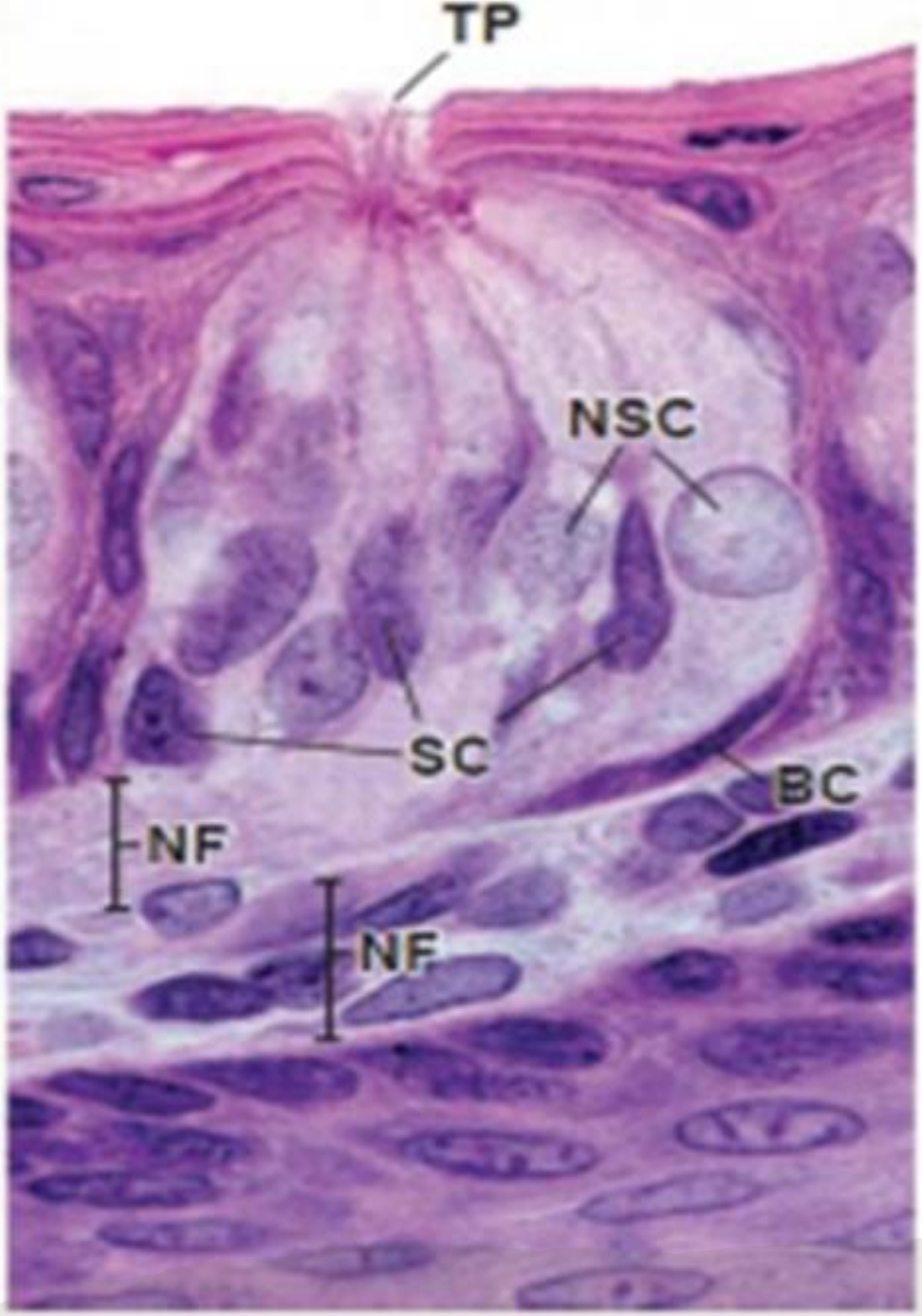

GLANDS ASSOCIATED WITH THE DIGESTIVE SYSTEM

Part I

SALIVARY GLANDS

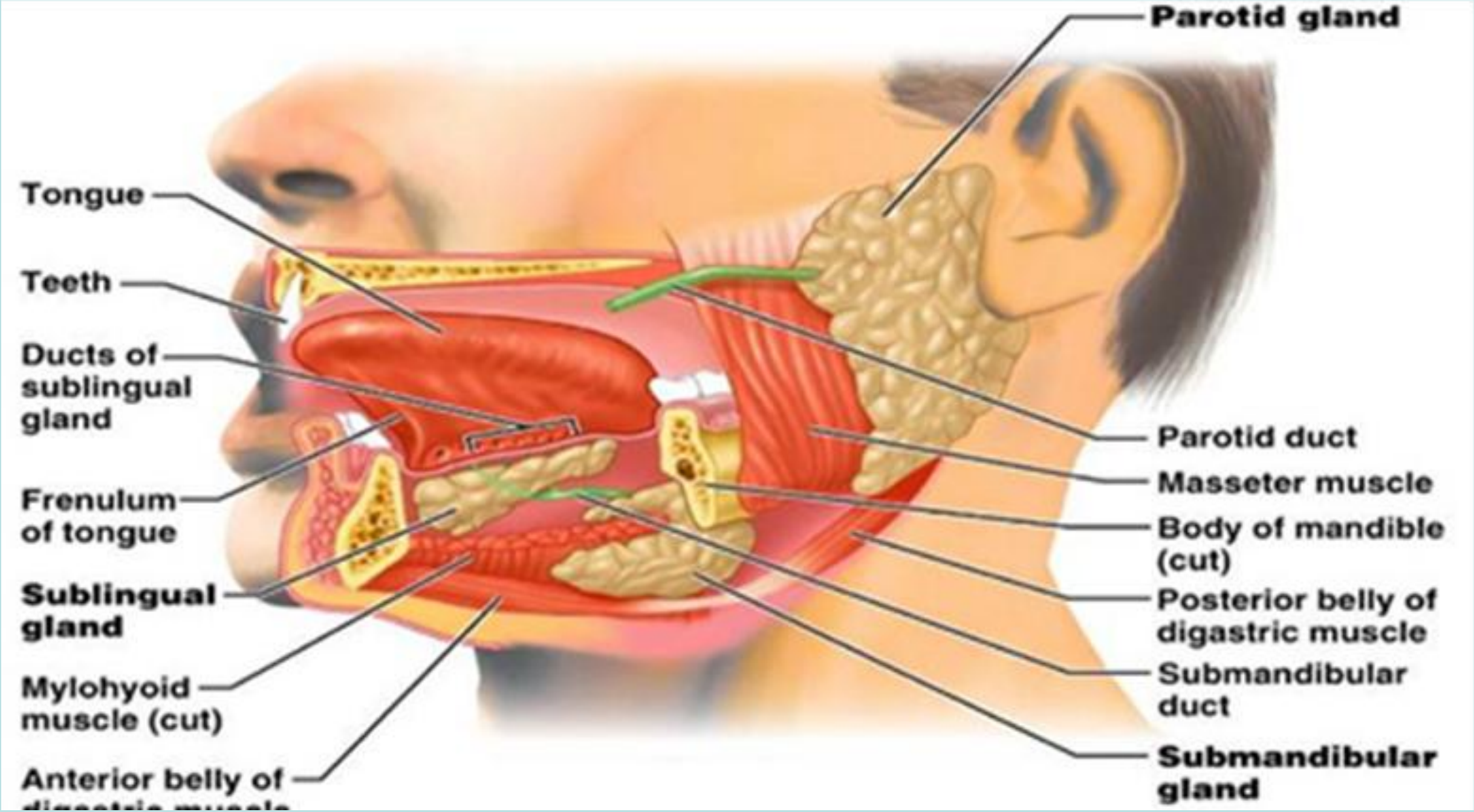
Parotid gland
Tongue
Teeth
Ducts of sublingual gland
Frenulum of tongue
Sublingual gland
Mylohyoid muscle (cut)
Anterior belly of
Parotid duct
Masseter muscle
Body of mandible (cut)
Posterior belly of digastric muscle
Submandibular duct
Submandibular gland

- 1. **Main (major) salivary glands**: compound tubule-alveolar exocrine glands secreting 90% of saliva. They include two parotid glands, two submandibular glands and two sublingual glands.

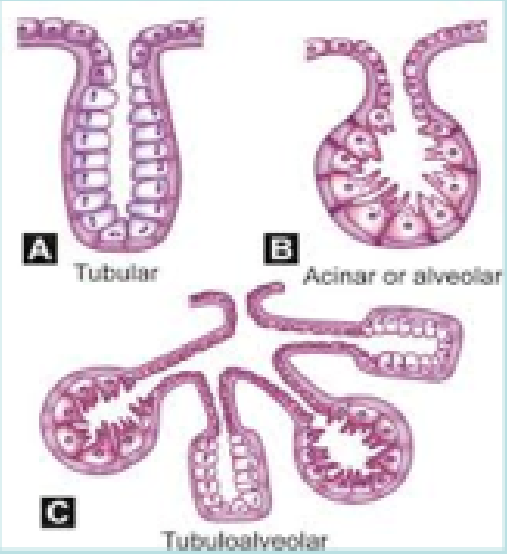

- 2. **Accessory (minor) salivary glands**: branched tubule-alveolar exocrine glands secreting 10% of saliva. They are scattered in submucosa of oral cavity, tongue, tonsils and lips (as buccal, lingual, palatine and labial accessory salivary glands respectively

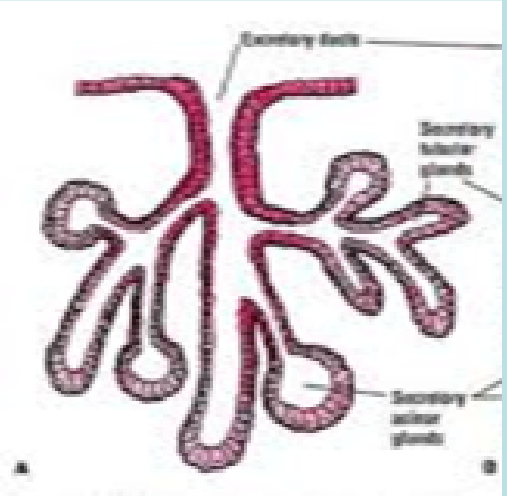

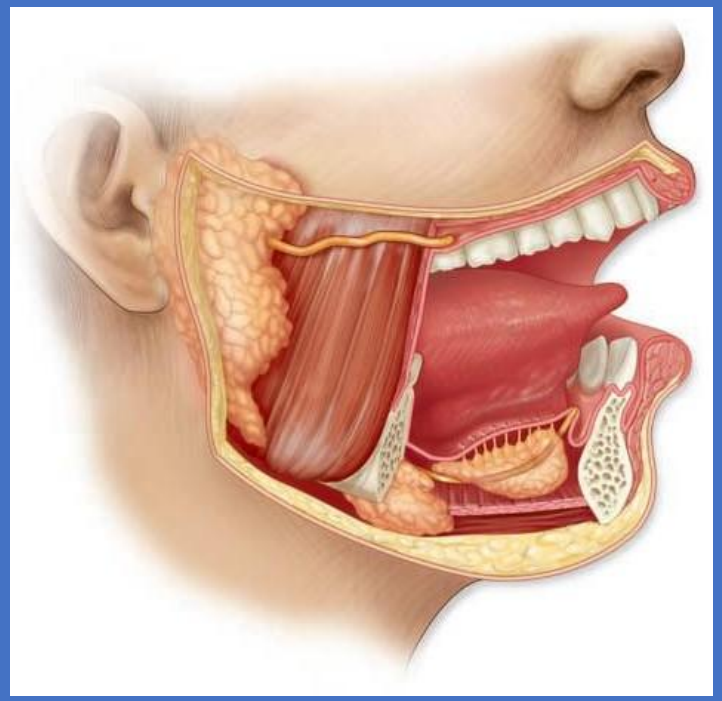

Salivary glands:

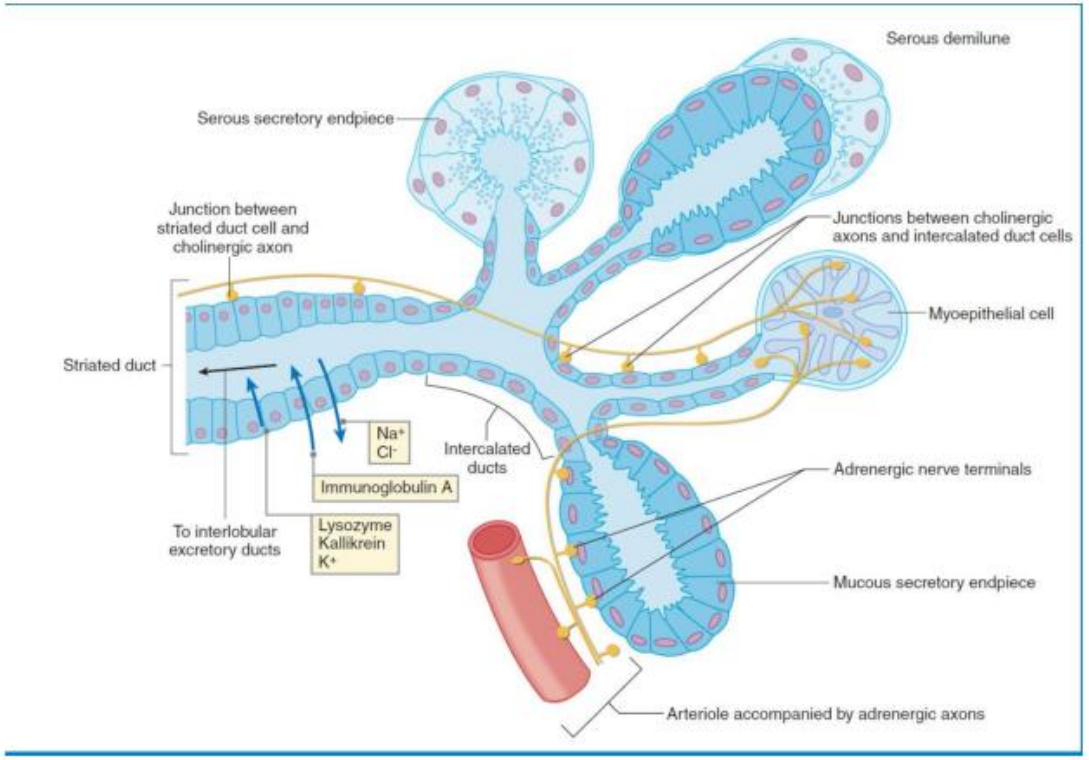

Salivary glands

- Exocrine glands in the mouth produce saliva, which has digestive, lubricating, and protective functions.
- In addition to numerous minor salivary glands located throughout most of the oral mucosa, there are three pairs of major salivary glands; the parotid, submandibular and sublingual glands.

(1) Secretory units:

- There are 3 types of secretory units:

  - Serous acini - Mucus acini - Mixed acini

- Each secretory unit is covered by contractile myoepithelial cells ,thereby expressing the secretions into a series of ducts of increasing diameter that connect to the oral cavity

A **serous acinus** secretes proteins in an isotonic watery fluid.
A **mucous acinus** secretes secretes mucin - lubricant
In a mixed serous-mucous acinus, the **serous** acinus forms a serous **demilune** around **mucous**acinus.
The secretory units merge into **intercalated** ducts, which are lined by simple low cuboidal epithelium, and surrounded by myoepithelial cells.
These ducts continue on as **striated ducts.** These have a folded basal membrane, to enable active transport of substances out of the duct.
The striated ducts lead into **interlobular** (excretory) ducts, lined with a tall columnar epithelium

Salivary glands

- Exocrine glands in the mouth produce saliva, which has digestive, lubricating, and protective functions.
- Minor salivary glands
- Major salivary glands
  - Parotid gland
  - Submandibular gland
  - Sublingual gland
- Three types of secretory units
  - Serous acini
  - Mucous acini
  - Mixed acini

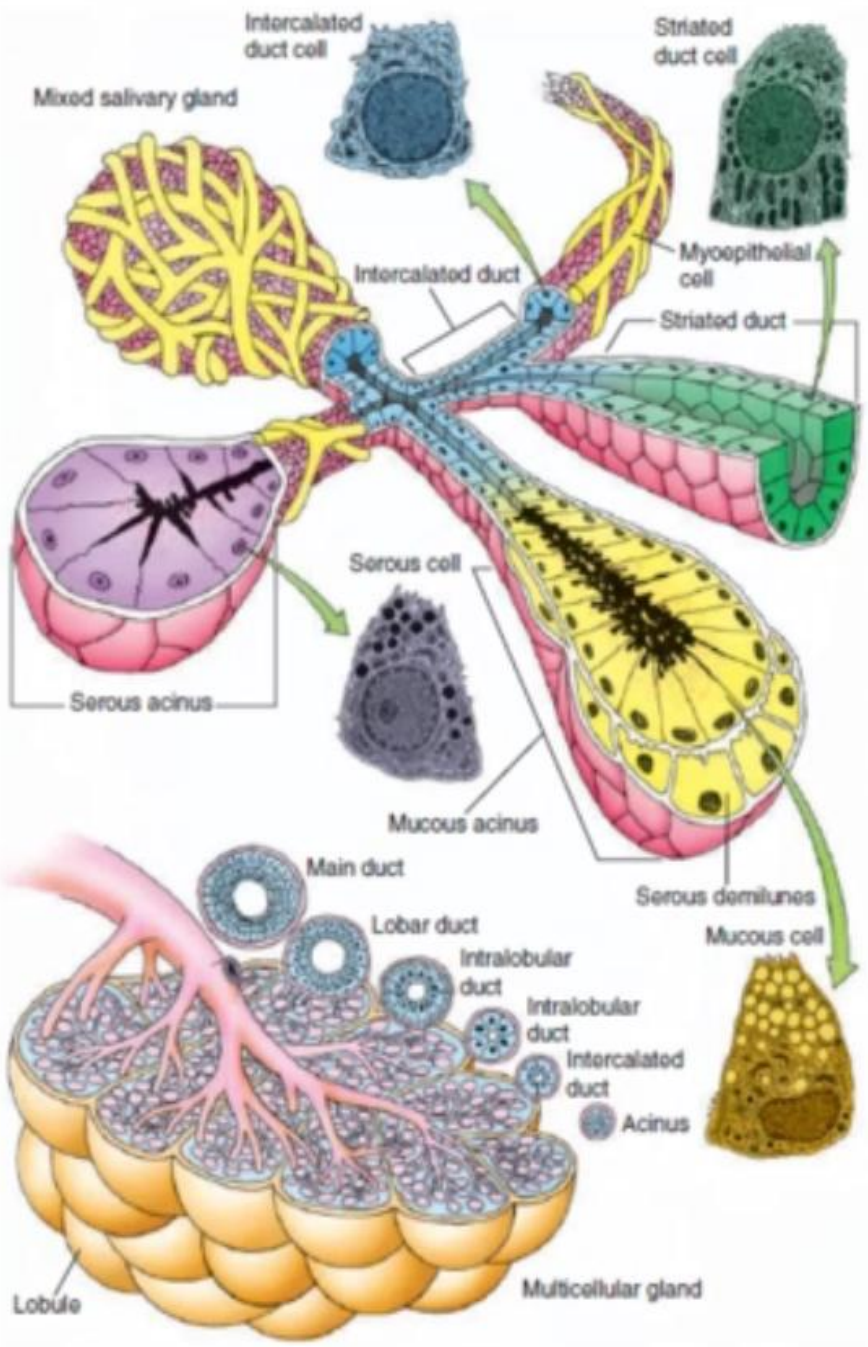

Salivary glands

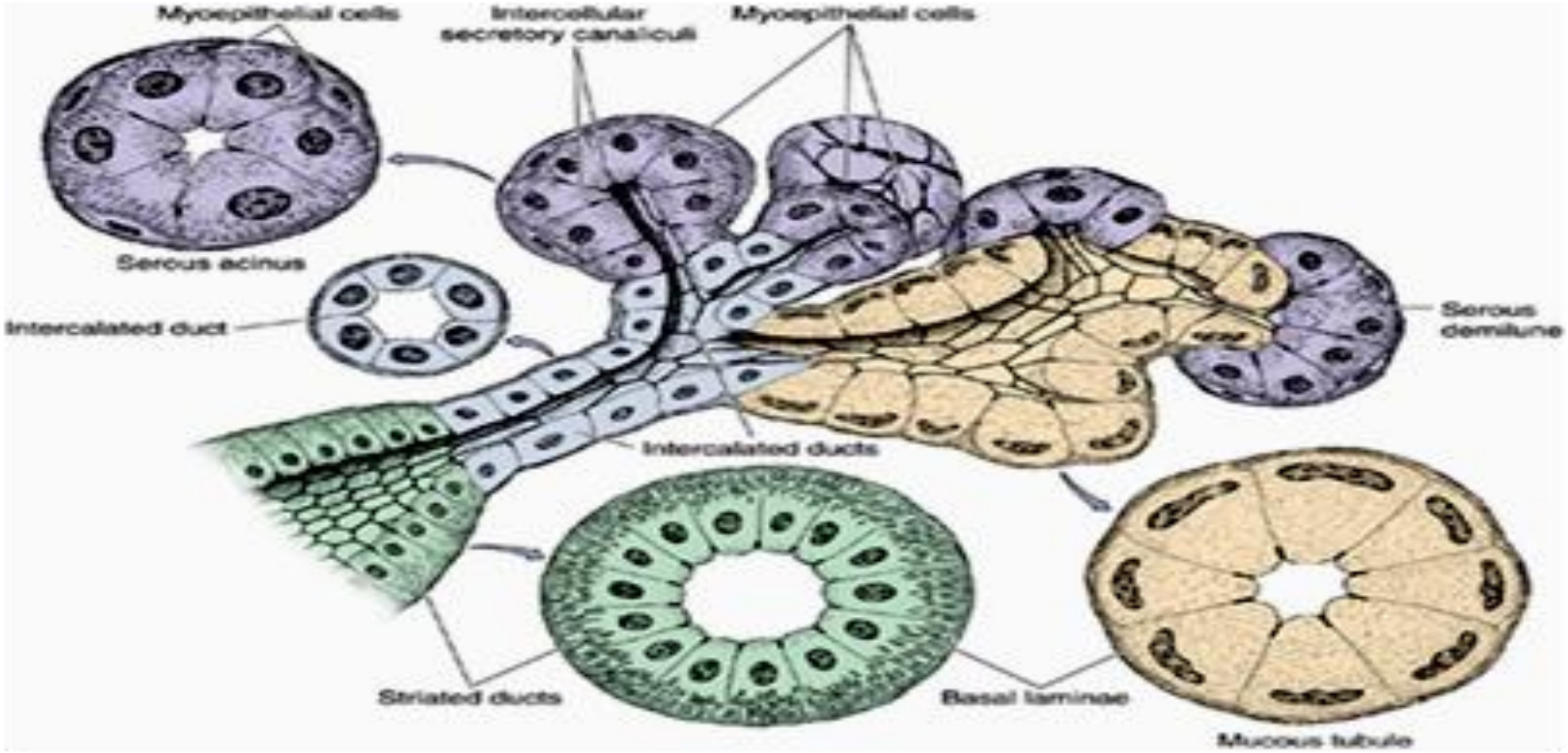

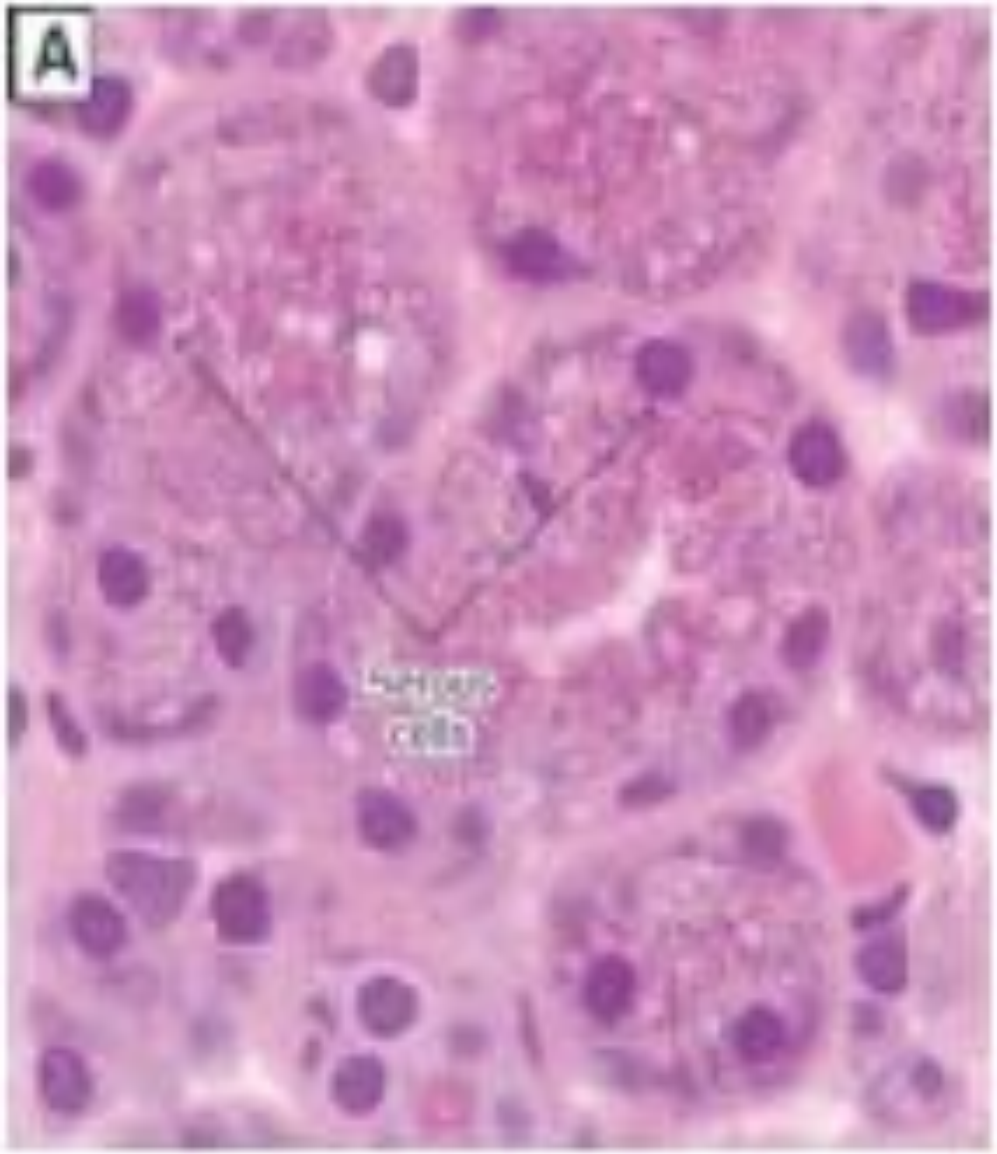
A

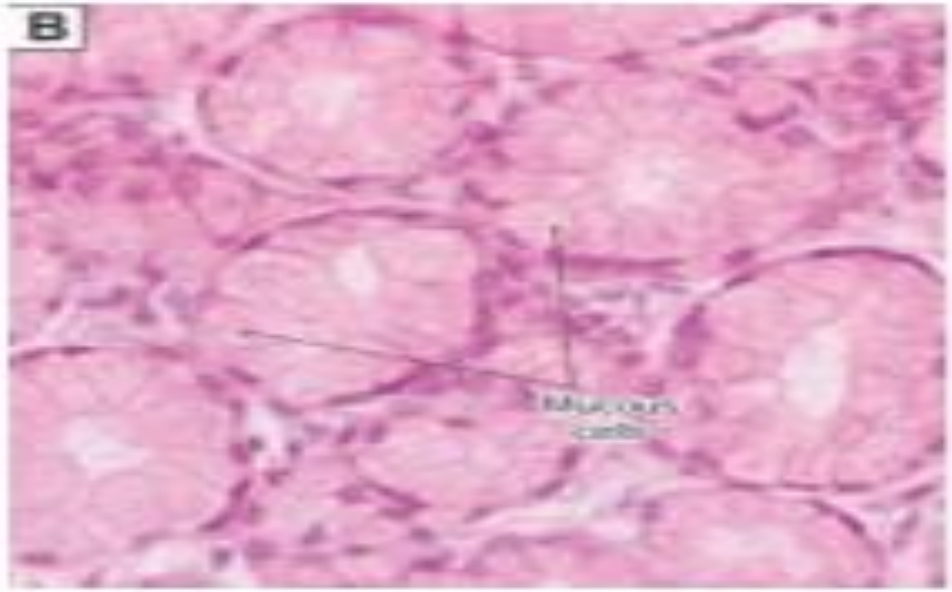
B

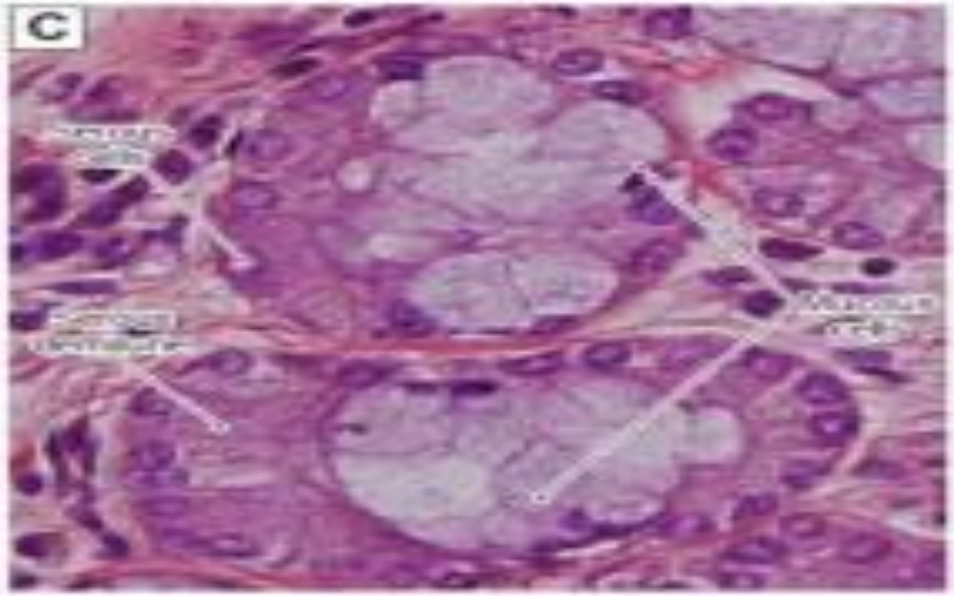
C

Secretory units

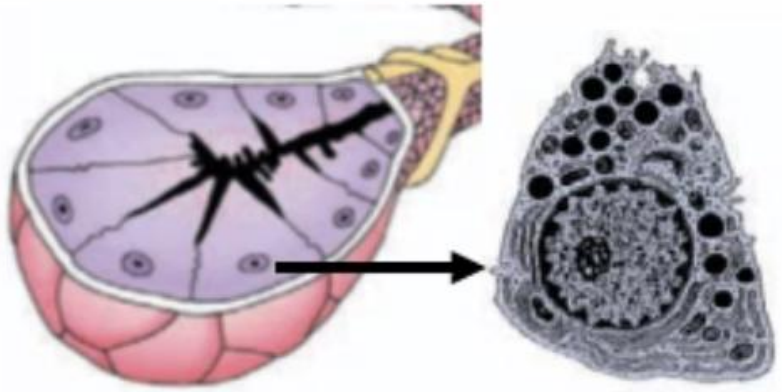

Serous acini:

- **Have** pyramidal cells with round nuclei and cytoplasm that are highly stained owing to the presence of many secretory vesicles containing serous proteins.

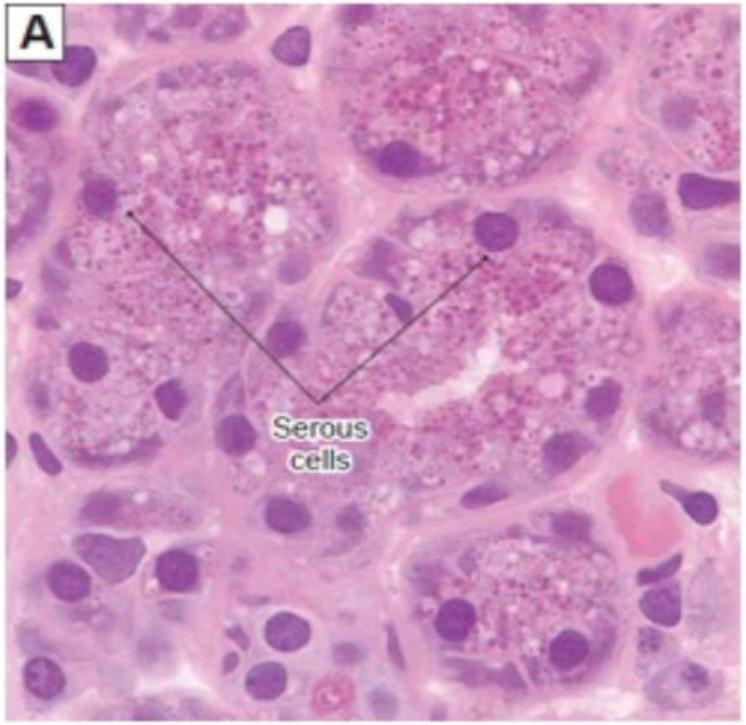

Secretory units

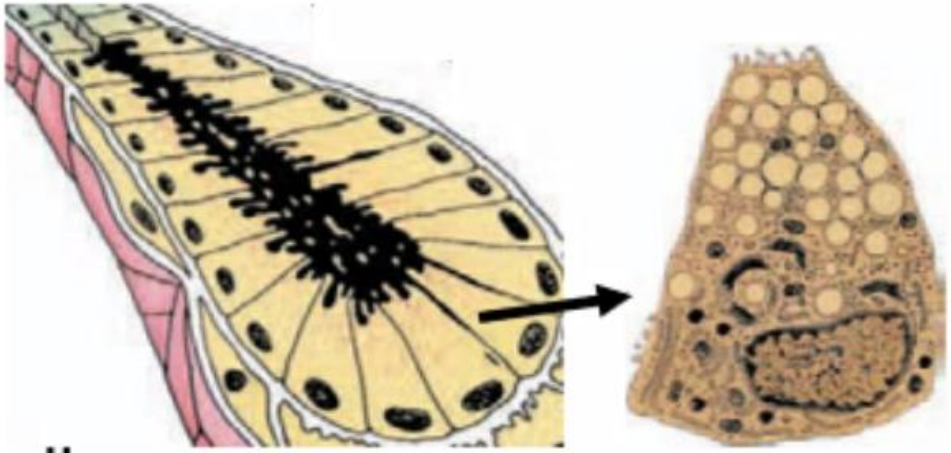

2. Mucous acini:

- Composed of acinar cells with small flattened, basally located nuclei and lightly stained cytoplasm owing to the presence of mucous proteins within secretory vesicles that fail to stain well with common histologic stains.

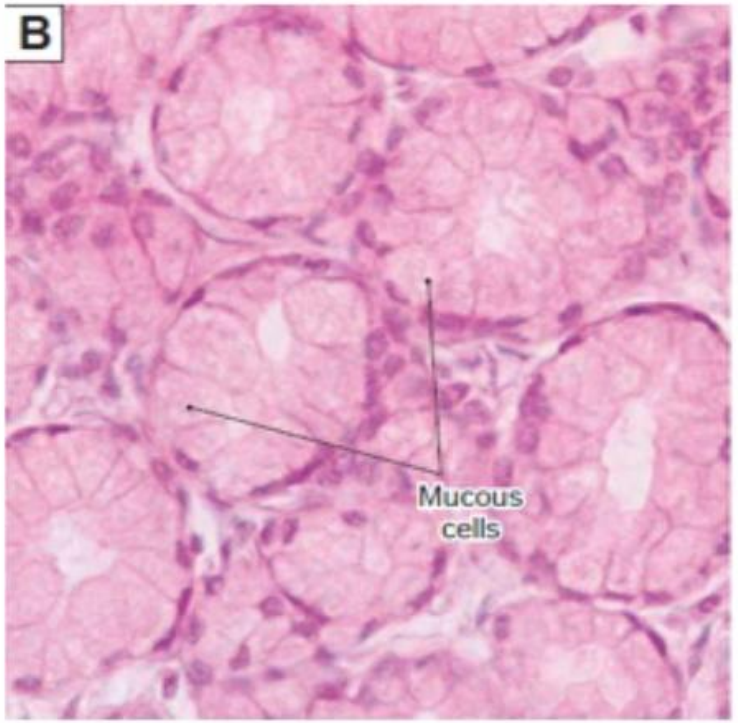

e Favorites Help

Secretory units

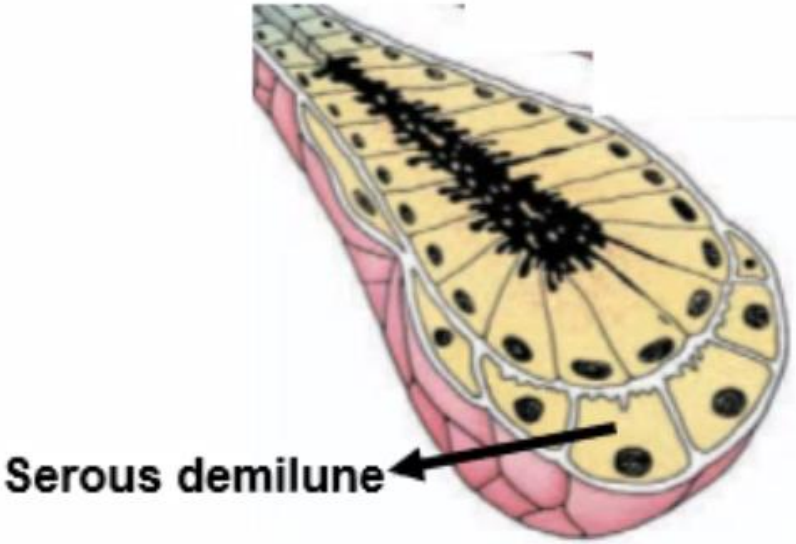

3. Mixed acini (sero-mucous):

- Composed of mucous cells capped by a few serous cells as **serous demilunes**.

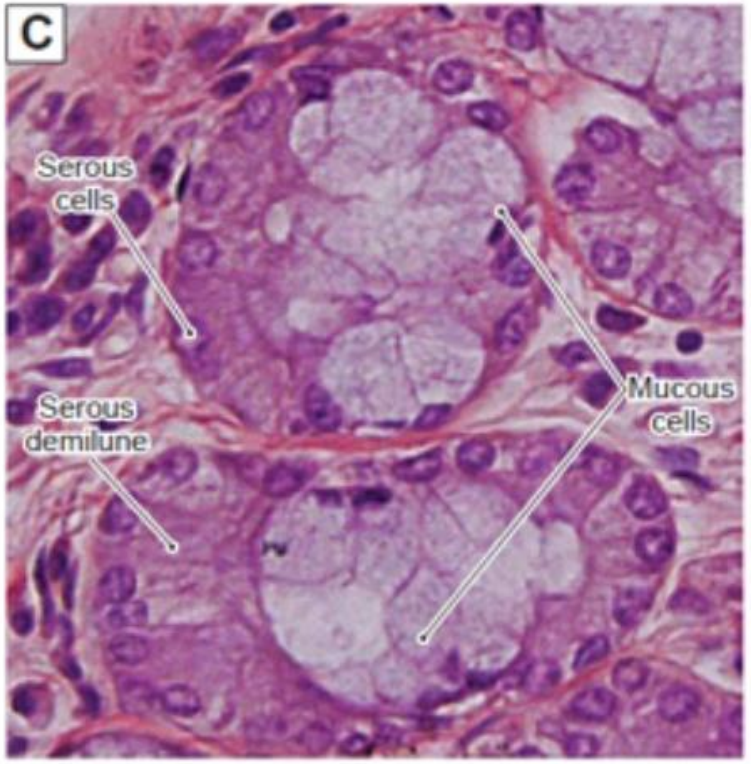

Serous acini	Mucous acini
• Small diameter and narrow lumen • Less numerous cells which are: ○ High cuboidal with central rounded nuclei ○ More basophilic (rER and zymogen granules) ○ Non-clear boundaries • Secretion is serous needing: ○ Few basket cells ○ Many canaliculi • Examples: ➢ Parotid glands ➢ Von-Ebner minor salivary glands	• Large diameter and wide lumen • More numerous cells which are: ○ Low cuboidal with basal flat nuclei ○ Pale and vacuolated (dissolved mucinogen granules) ○ Clear boundaries • Secretion is mucous ne ○ Many basket cells ○ Few canaliculi • Examples: ➢ Submandibular salivary glands ➢ Sublingual salivary glands

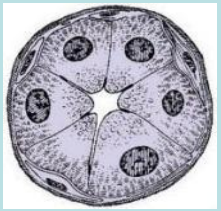

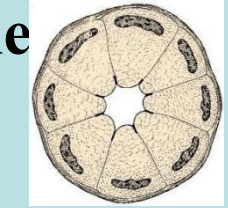

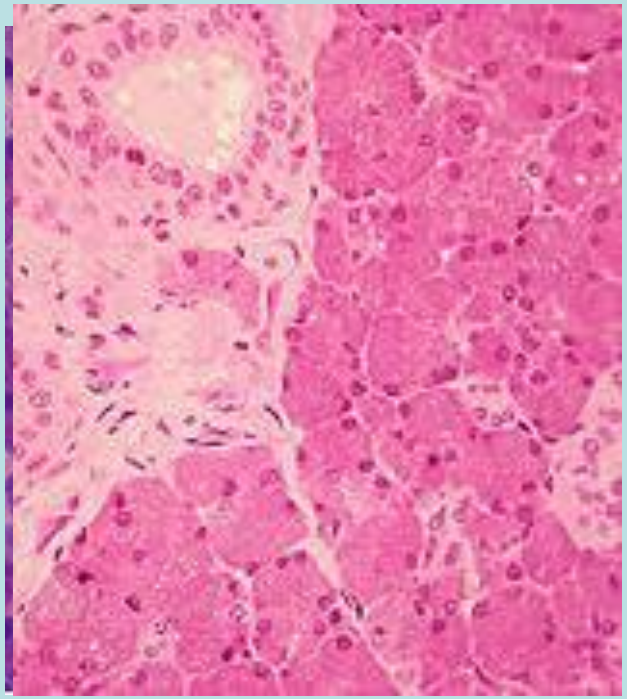

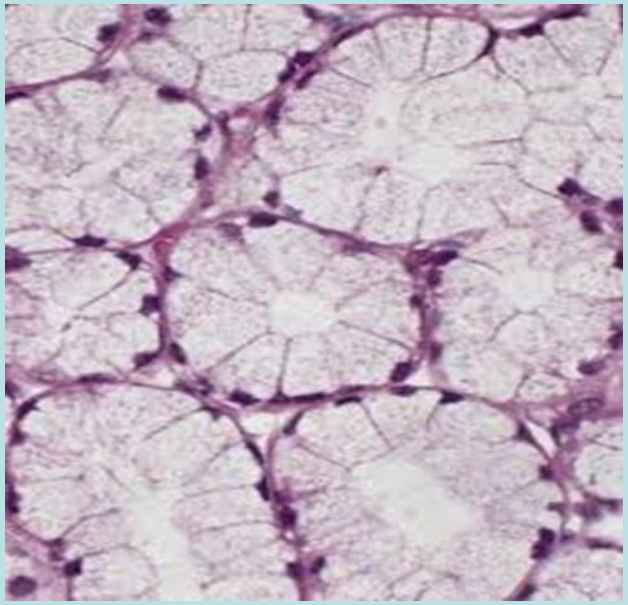

Ducts of salivary glands

- **Intercalated ducts:**
  - Lined by **simple cuboidal epithelium**
- **Striated ducts:**
  - Lined by **simple columnar epithelium**
  - Have **thin longitudinal lines (striations)** that are visible in light micrographs of the cytoplasm of duct cells
- **interlobular ducts:**
  - Possessing a **stratified cuboidal** or **stratified columnar epithelium**

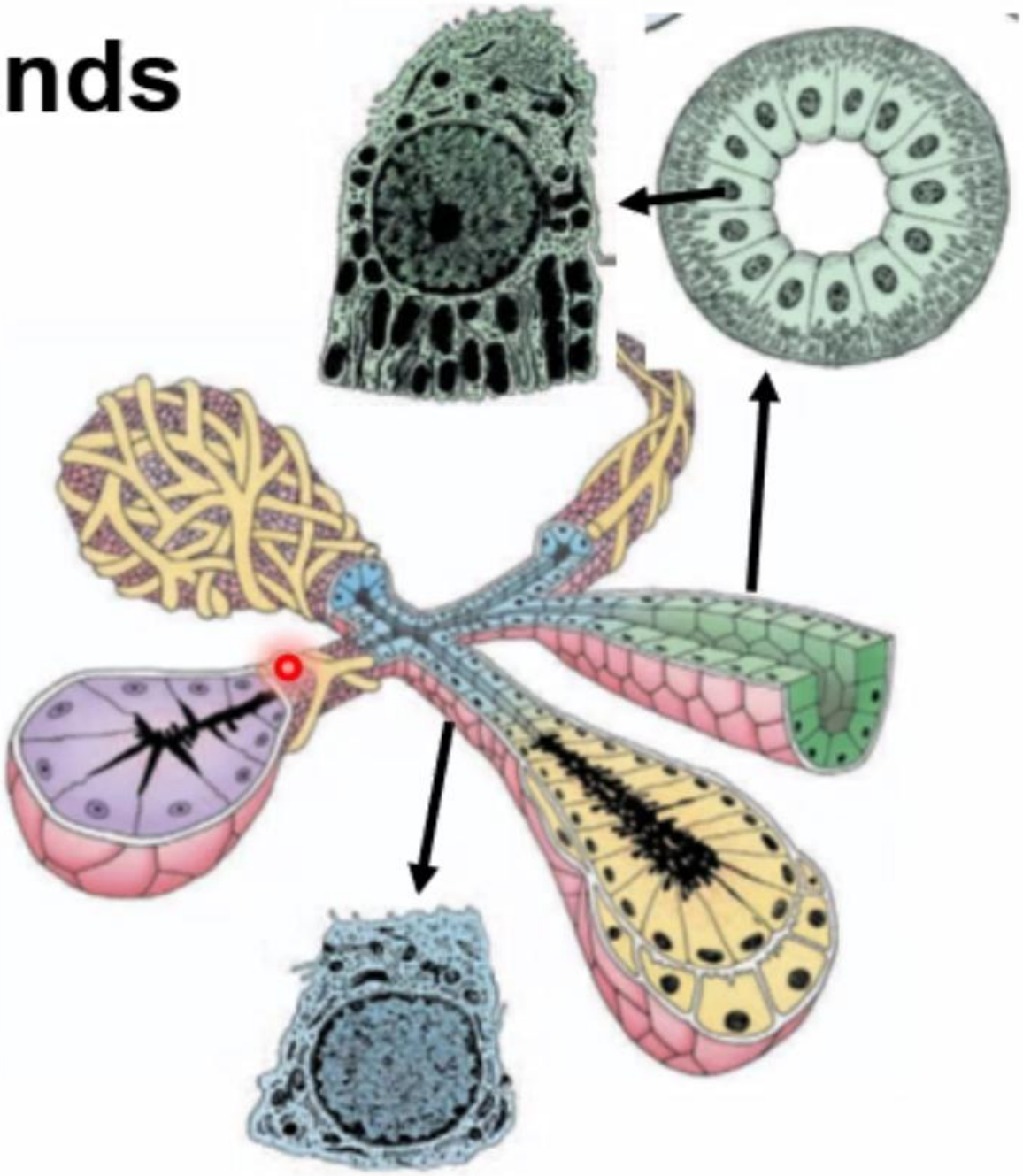

(2) Duct System

. Intercalated ducts unit together to form striated ducts with a lining
epithelium of simple columnar epithelium type.
Striated ducts are named for the thin longitudinal lines that are visible in light micrographs of the cytoplasm of duct cells. They are typical cells specialized for ions transport.

- interlobular ducts
- Interlobar ducts
- Main salivary duct

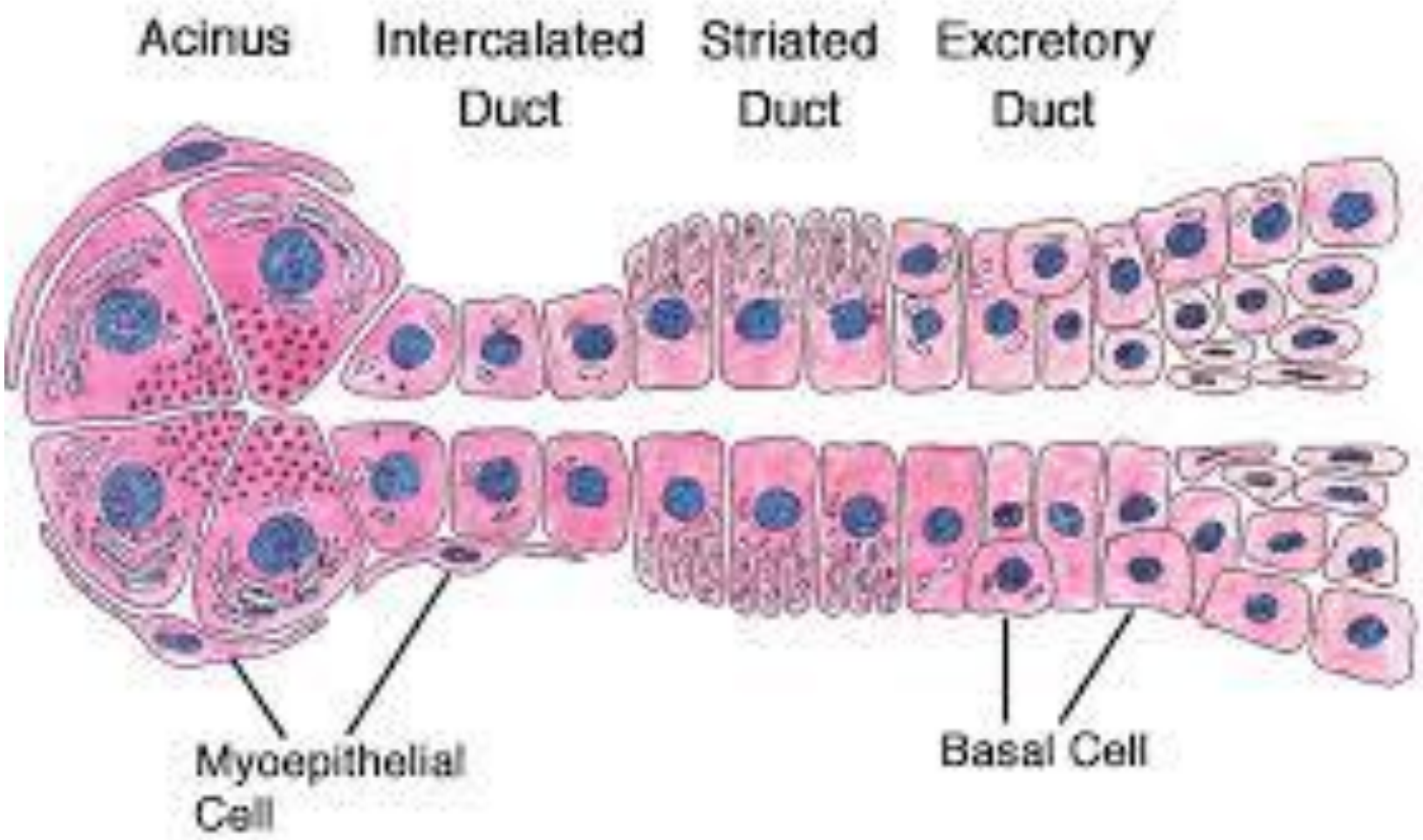
Acinus
Intercalated Duct
Striated Duct
Excretory Duct
Myoepithelial Cell
Basal Cell

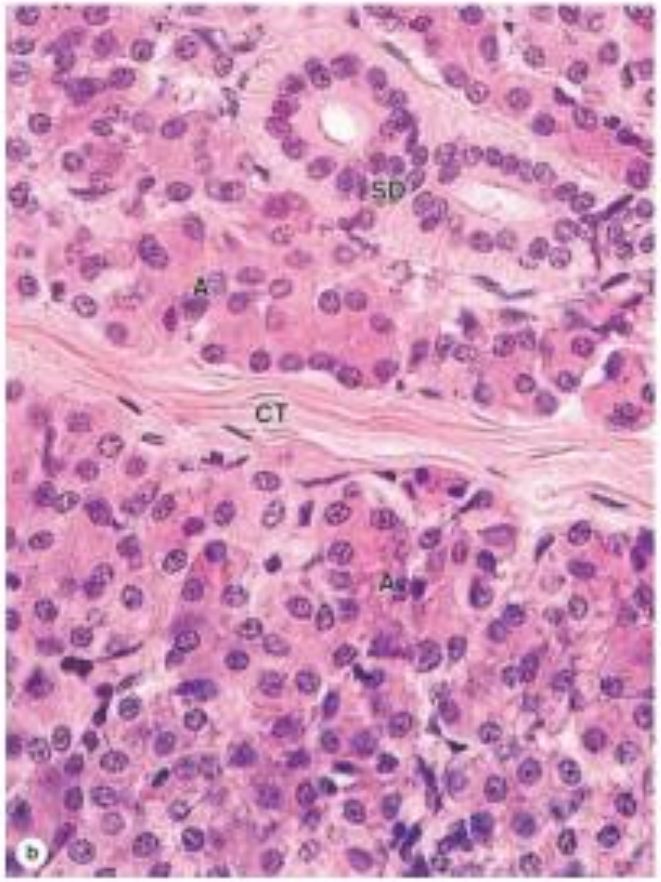

The parotid gland is composed entirely of serous acini.

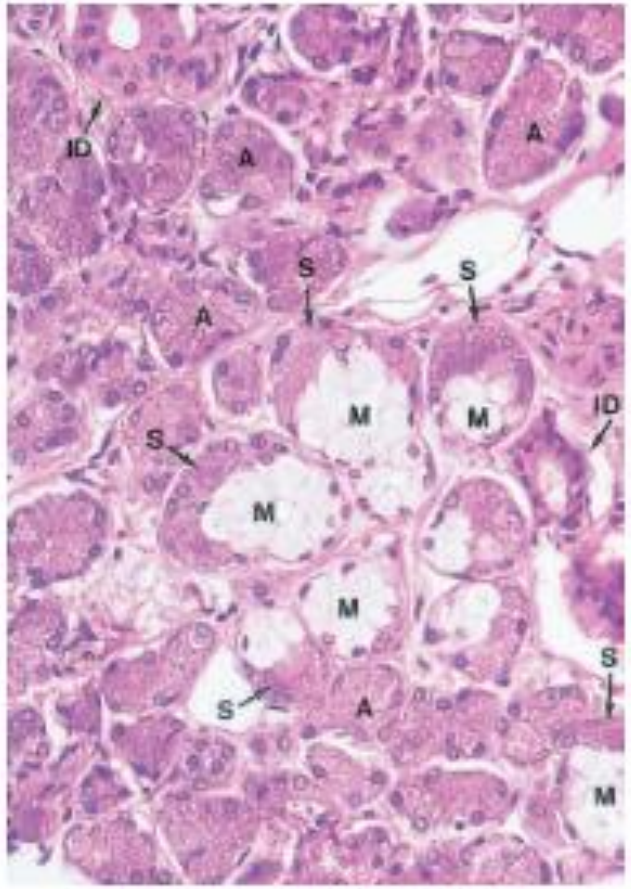

Submandibular gland contains mostly serous but also a few mucous acini.

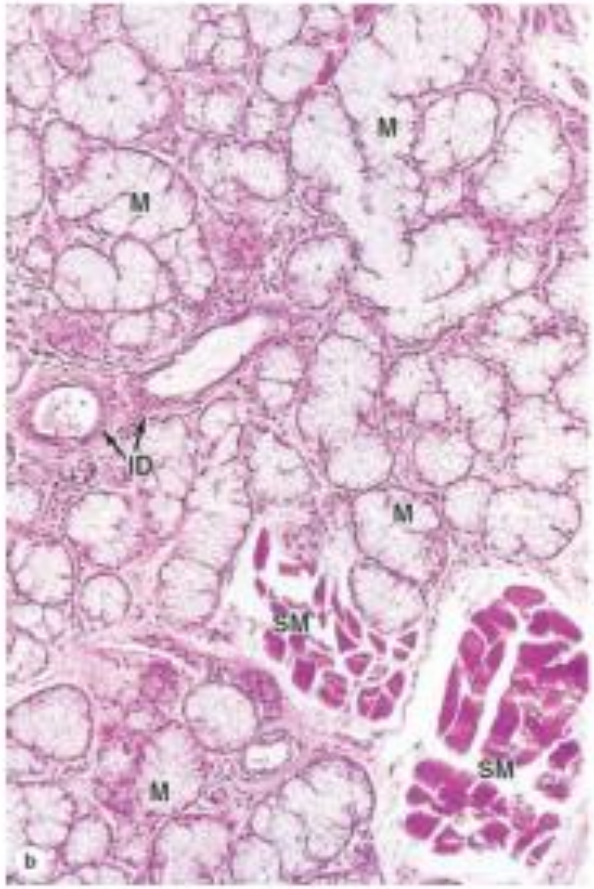

Sublingual gland contains mainly mucus acini.

- 1 - **Parotid Gland:**
- It is the largest salivary gland.
- The C.T. capsule is well developed .
- The secretory units are purely serous.
- The intralobular ducts are praticulary prominent.
- The main duct opens into mouth vestibule opposite upper 2nd molar tooth.

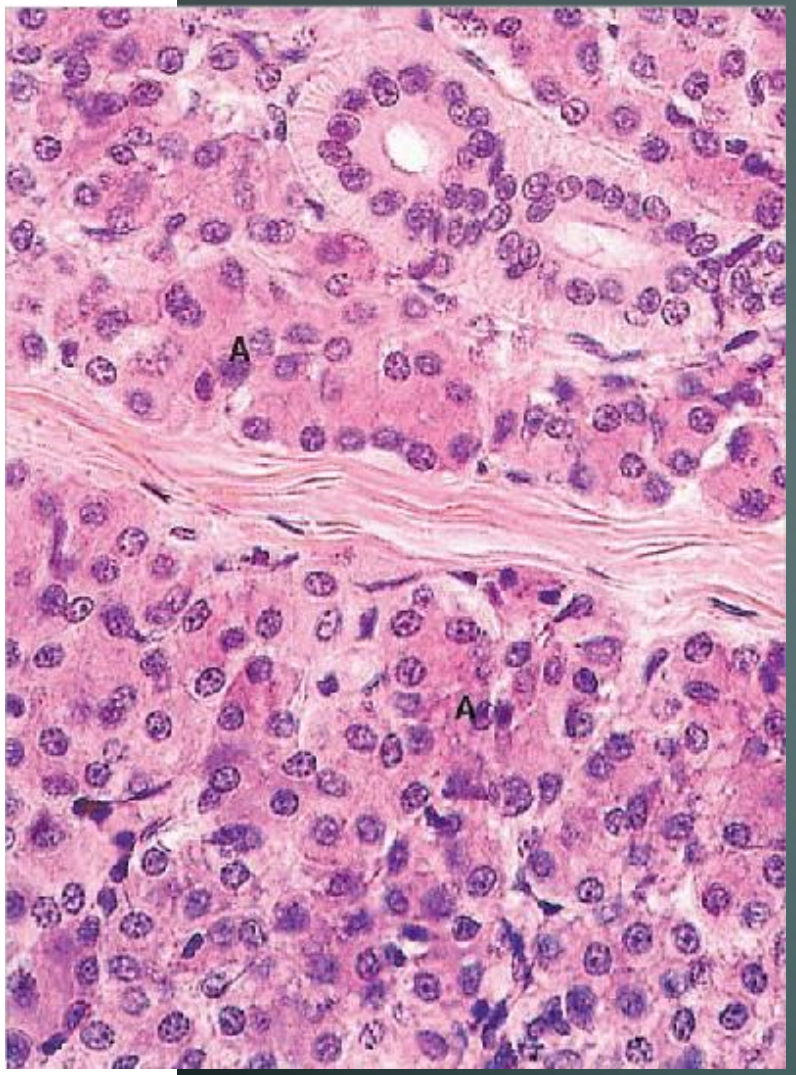

- 2 - **Submandibular Glands:**
- The C.T. capsule is extensive and forms numerous septa.
- The majority of the secretory units are of serous type (80%). The remainder is mucous. The number of serous demilunes is limited.
- The secretory(striated) ducts are long so, they are characteristically prominent in histological sections..
- The main duct opens into the mouth cavity beneath the tip of the tongue.

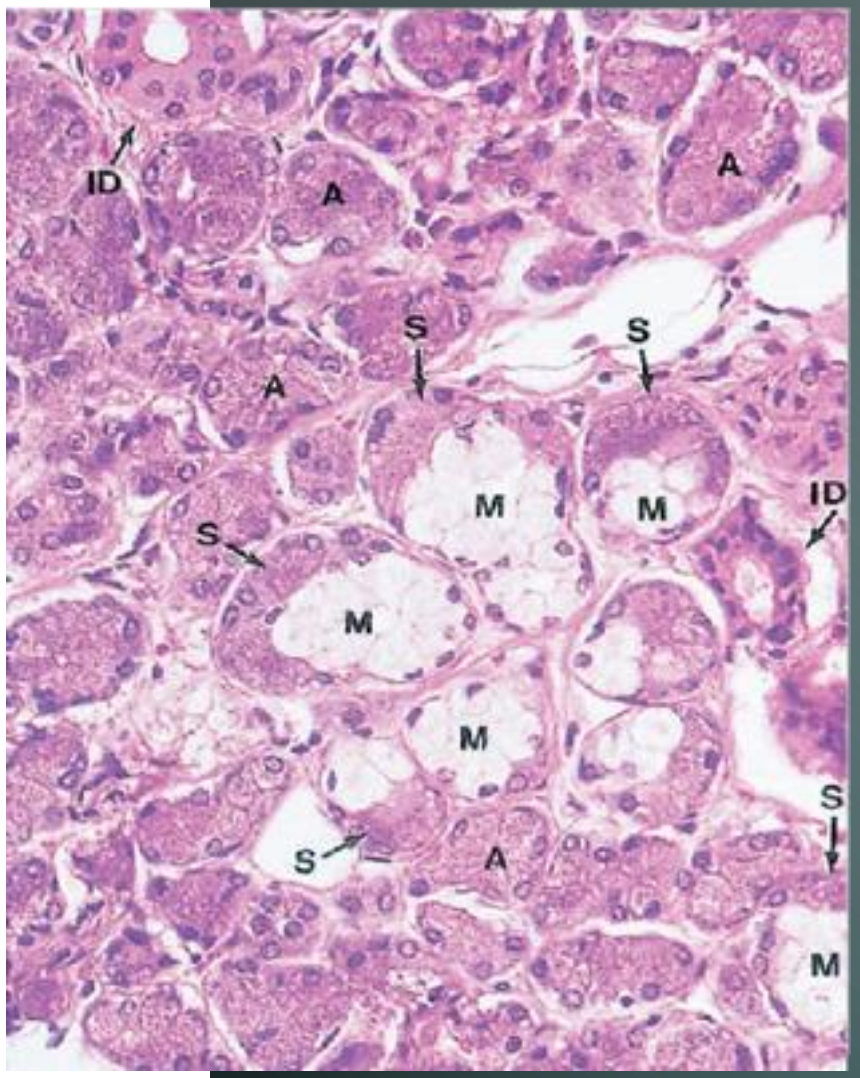

3 - Sublingual Glands.

- It is very small.
- The majority of the secretory units are of mucous type.
- Intralobular ducts are shorter, being fewer in number than those of the parotid and submandibular and formed mainly of striated ducts.
- The duct system does not form a terminal duct. Instead, several ducts open into the floor of the mouth.

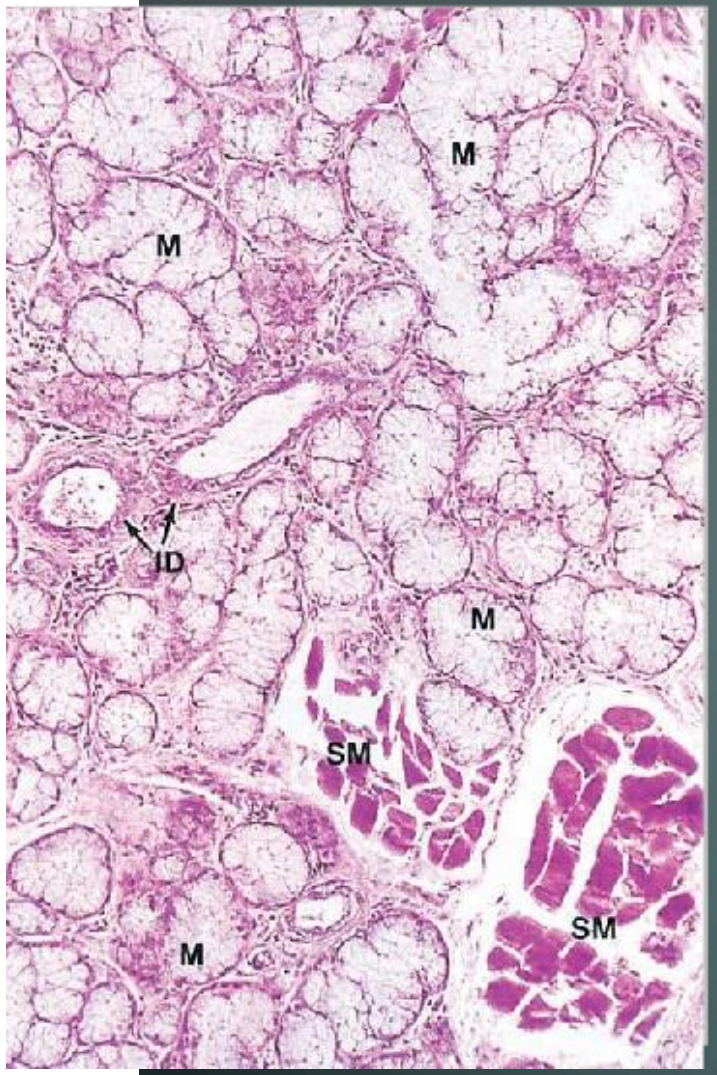

General structure of the GI tract

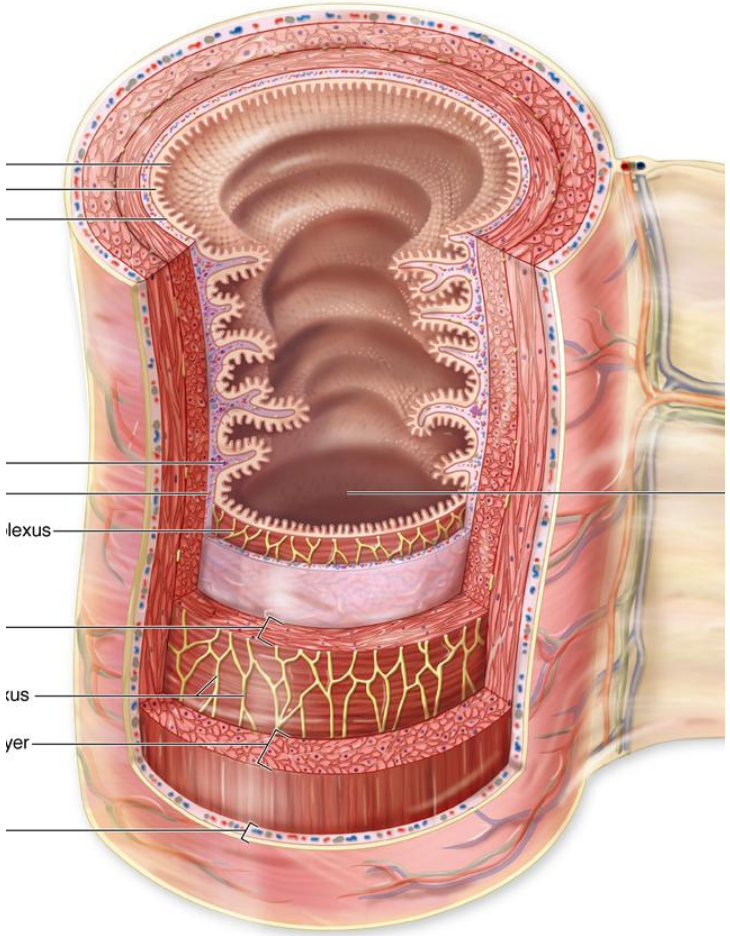

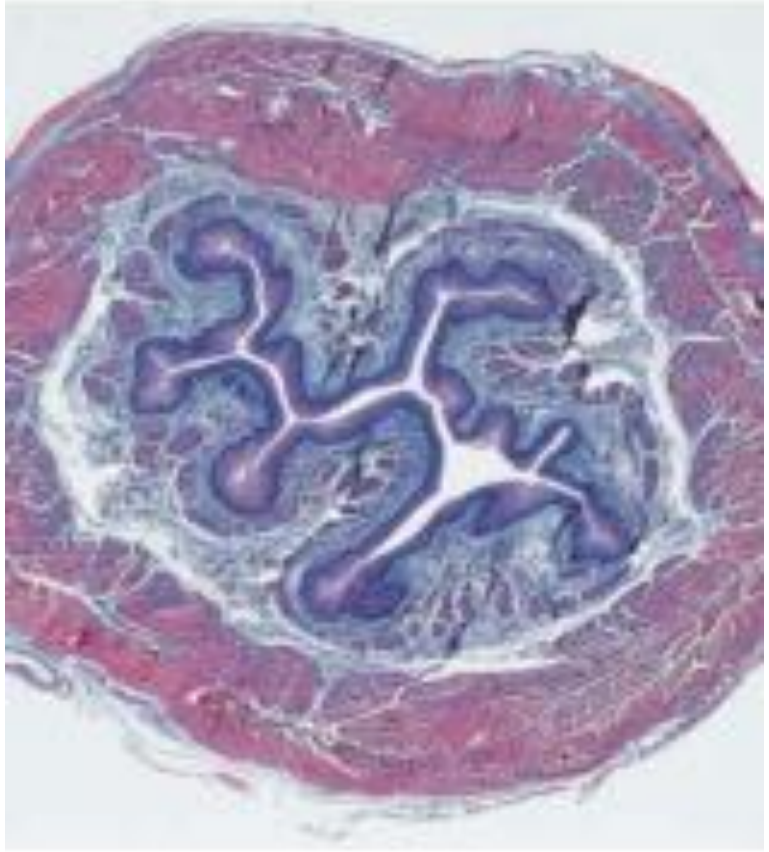

- **The entire gastrointestinal tract has common structural characteristics made up of four main layers:**

1 - Mucosa
2- Submucosa
3 - Muscularis mucosa
4- Adventitia or serosa

1-Inner mucosa consists of:

a) Epithelium is simple columnar except the oesophagus and the anal canal.

b) Lamina propria is formed of CT and contains:

Simple or compound gland, Lymphoid infiltration or lymphoid nodules.

c) Muscularis mucosa:

Is formed of an inner circular and an outer longitudinal layer of smooth muscle fibers.

2- Submucosa:

Is formed of dense CT with many blood and lymph vessels, and also contains submucosal nerve plexus (Meissner's plexus).

It may contain lymphoid follicles or compound glands only in esophagus and duodenum.

3- *Musculosa:*

- **Usually, it is formed of 2 layers (inner circular and outer longitudinal) of smooth muscle fibers.**
- **Auerbach's nerve plexus is found between the 2 layers.**

4- Adventitia or serosa:

If covered by a simple squamous epithelium , is termed a serosa; when it lacks a mesothelial covering (as in certain portions of the esophagus and duodenum), is called an adventitia.

- **Innervation of the alimentary canal is accomplished by the enteric nervous system (whose neurons are located in Meissner [submucosal] and Auerbach [myenteric] plexuses.**

.

Esophagus

- **The mucosa of the esophagus is lined by a stratified squamous epithelium.**

- **Esophageal cardial glands can be found within the mucosa. These branched tubular glands secrete a slightly alkaline mucus .**

- **The submucosa contains Submucosal glands which are compound tubulo-alveolar glands that secrete a slightly acid mucus to lubricate the lumen.**

- **The muscularis is bi-laminar with an inner concentric and outer longitudinal arrangement. The muscularis externa changes from skeletal muscle proximally to smooth muscle distally.**

- **The adventitia is unremarkable.**

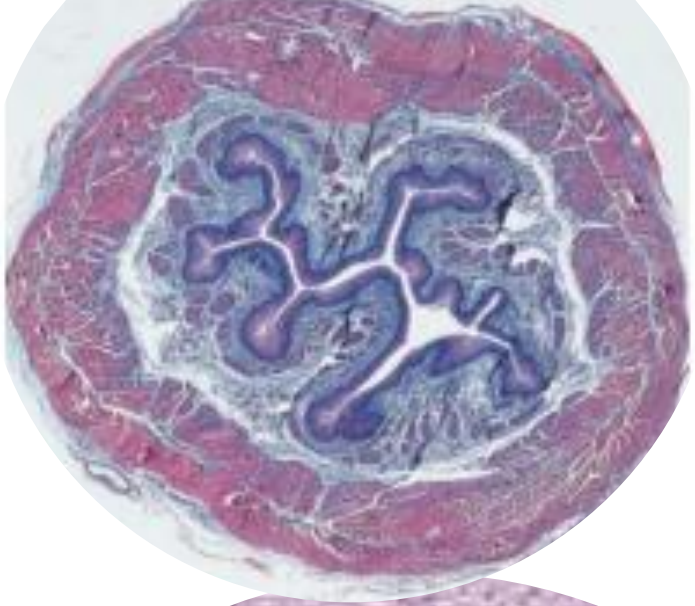

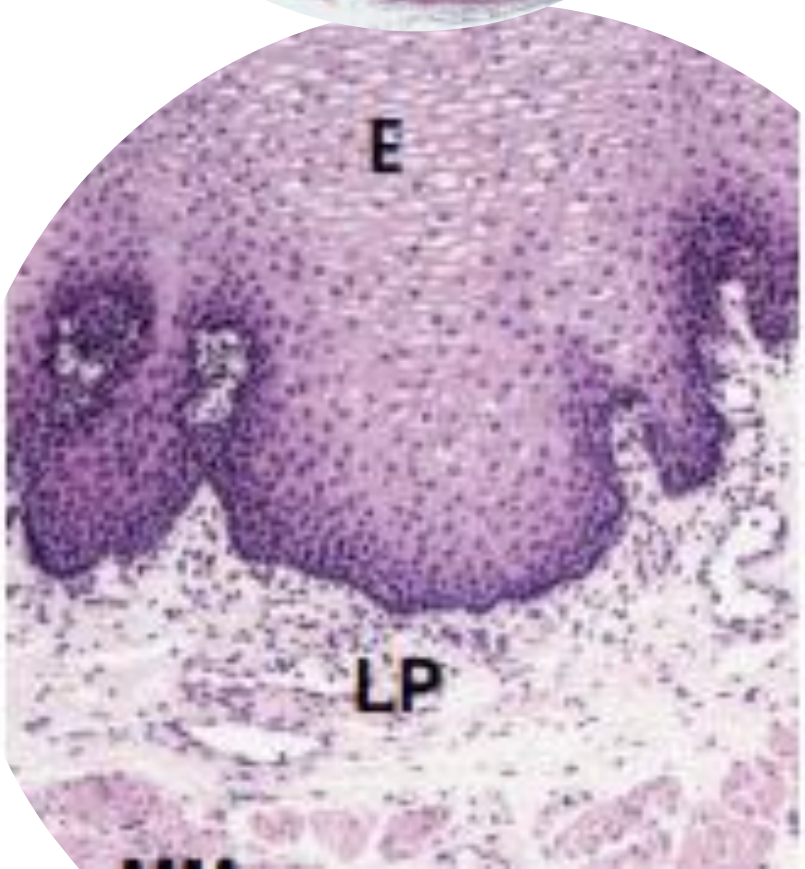

Esophagus

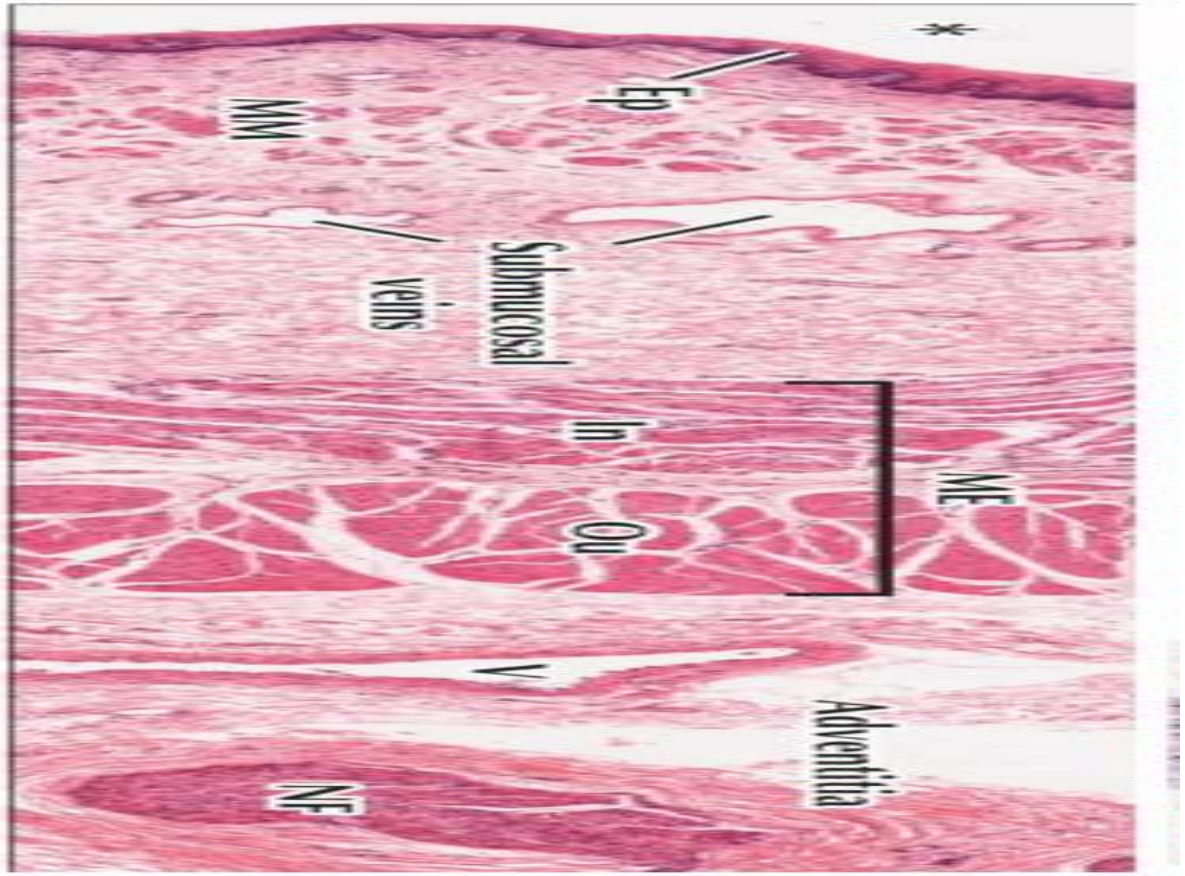

References:

Junqueira's Basic Histology (Text and Atlas) (2018) 15 th edition.

Elsevier's Integrated Histology (2007) 1st Edition.

Self assessment

1. **The type of epithelium associated with the vermilion zone of the lips is:**

a. Stratified squamous nonkeratinized.
b. Pseudostratified ciliated columnar.
c. Stratified squamous keratinized.
d. Stratified cuboidal.
e. stratified columnar.

2. Concerning lingual papillae;

a. Filiform papillae contain taste buds.
b. Vallate papillae are found all over the dorsum of the tongue.
c. Fungiform papillae lack taste buds.
d. Filiform papillae help movement of food during chewing.
e. Foliate papillae are located along the sulcus terminalis.

THANK YOU